

REFERENCES :

1. Dene, M. J. Gould, L. V and Brozin, I, H : Gall stone ileus, Brit J. Surg. 1962, 49 : 660.
2. Brockis, J. G and Gilbert, M. C: Intestinal Obstruction by gall stones — Review of 179 cases; Brit J Surg 1956, 44 : 461.
3. Kirby C. Kirkland and Edmund J. Croce : Gall Stone Intestinal Obstruction. Reviies of the literature and presentation of 12 cases, including 3 recurrences. J Am Med Ass 1961, 117 : 1753.
4. Logan, C. J. M. J. R. Coll Surg Edinb 1978, 23 : 30.
5. Thrope, J.A.C. : Gall stone ileus J. R. Coll Surg Edinb 1979 24 : 298.
6. Morlock, C. G; Shocket, E; and Ranine, W. H : Intestinal Obstruction due to gall stones. Gastroenterology 1956, 30 : 462.
7. Turner, G. Grey Br. J. Surg 1932, 20 : 26.
8. Bridenbaugh, R. B; Bridenbaugh, J. H and Berg, H. Milton Amer J Roentgenol 1957, 77 : 684.
9. Mclaughlin, G. W, Jr and Raines, M: Obstruction of Alimentary tract from Gall Stones : Amer J Surg 1951, 81 : 424.
10. Noskin, E. A. and Tannenbaum, W. J; Recurrent gall stone ileus, case report surgery 1952, 31 : 599.
11. Nemir, P. Jr.: Gall Stone ileus : Report of 8 cases Surg Gynae Obst 1952, 94 : 469.

THE AUTHORS

Dr. S. M. Abbas Hussain, MBBS, Resident Medical Officer,
Dr. Mohd. Shamim, FRCS, Consultant Incharge, Surgical Unit-I,
Abbasi Shaheed Hospital, Karachi.

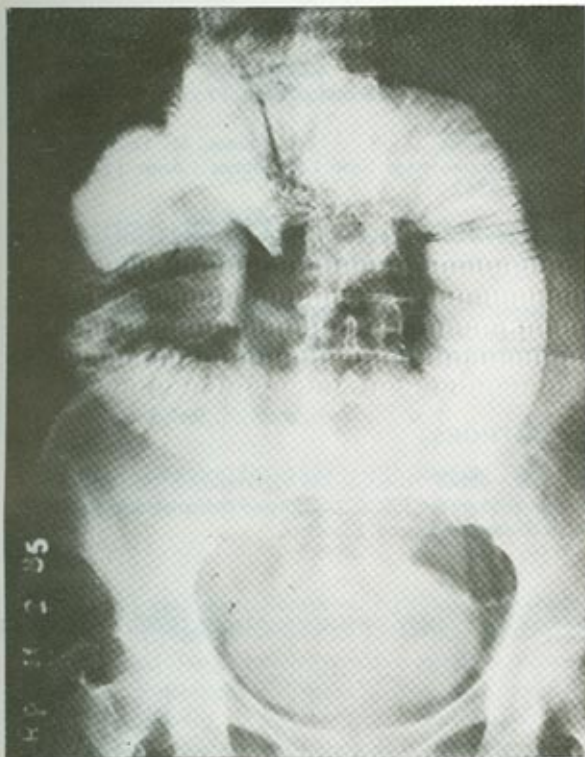


Fig. 1 Radiolucent stone in terminal ileum




Fig. 2 4 cm x 2.5 cm. gall stone

DISCUSSION :

Gall stones have been known to produce intestinal obstruction without marked abdominal distension². The obstruction stone usually leaves the gall bladder by way of a fistula into the duodenum, although less commonly, the tract may be into the stomach or colon^{2,4,5}. Rarely it may pass through the common bile duct³. It is estimated that the stone would have to be at least 2 cm in diameter to cause obstruction. The largest reported stone impacted in the transverse colon, was 17.5 cm in diameter⁷.

In this case the clinical picture of the patient did not suggest intestinal obstruction. There was visualisation of a calculus in the intestines. There was no air or contrast media in the biliary tree. Barium provoked complete obstruction and probably because of ulceration of the wall of ileum due to the long standing presence of the stone a perforation resulted.

In addition to the roentgenographic criteria for the diagnosis⁸, vomiting of stones⁹, palpation of stones through incisional hernia¹⁰ and rectally⁶ have been described.

The contrast media for the demonstration of fistula or stone in the gut should be preferably gastrografin, as it is absorbable and safer. Its flow properties enhance the chances of demonstrating a cholecystoduodenal fistula.

The male to female ratio for the cases of gall stones ileus is 1 : 7². The reported relation to biliary diseases is 0.5% whilst in our experience it is 0.043%. Prior to 1940 the mortality rate of this disease was 60%. While in recent series the mortality is 12.5%. Because of the high mortality rate early cholecystectomy in all cases of gall stone and early diagnosis of this condition with a high index of suspicion, especially in small bowel obstruction, past 60 years of age is recommended. Emphasis should be laid upon adequate preoperative resuscitation, prophylactic antithrombotics and antibiotics to minimise morbidity and mortality after operation⁵.

During surgery no attempt should be made to explore the fistula. The only indication to explore the gall bladder region is the presence of additional stone in the gall bladder. Even then the advocated procedure, in such cases is the removal of stones and cholecystostomy.

Gall Stone Ileus

S. M. Abbas Husain, M. Shamim

Department of Surgery, Abbasi Shaheed Hospital, Karachi.

ABSTRACT :

A case of gall stone ileus associated with a mass in the right hypochondrium is reported and the diagnosis and treatment discussed.

Key Words : Gall stone — Mass right hypochondrium — Intestinal obstruction.

INTRODUCTION :

Gall stone ileus is responsible for 1.5% of all cases of small bowel obstruction¹, and 25% of cases of small bowel obstruction over 70 years of age¹. Recurrent gall stone intestinal obstruction is uncommon and only 16 cases have been reported in literature.

During the past 12 years there have been about 2300 admissions to the Abbasi Shaheed Hospital (ASH) for diseases of the gall bladder or biliary tree with a male to female ratio of 1 : 11. During the same period there was only one case of gall stone ileus : an incidence of 0.043% in patients with recognized gall bladder and biliary diseases.

CASE REPORT :

H. B. a 70 year old lady was diagnosed as a case of chronic cholecystitis with cholelithiasis and was advised surgery. Six months after the diagnosis she attended the emergency room with pain in the right hypochond-

rium and vomiting of two days duration. Physical examination revealed a globular tender 7.5 x 3.7 cm mass in the right hypochondrium which moved with respiration. Investigations at that time revealed Haemoglobin 10.8 gms, Leucocytes 11,500/mm, Polymorphs 80%, Lymphocytes 20%, Blood sugar random 120mg%, Blood Urea level 18 mg%, Serum Sodium 145 mEq/L, Potassium 4 mEq/L, Chloride 110 mEq/l, Bicarbonate 24 mEq/L.

She was diagnosed as a case of acute on chronic cholecystitis and treated conservatively. She improved and went home. On review after four weeks tender mass was found unchanged. The ultrasound examination revealed absence of stone from the gall bladder and confirmed the presence of an irregular mass of heterogeneous echogenicity adherent to the visceral surface of the right lobe of liver. A barium meal follow through showed a radiolucent shadow in the terminal ileum (Fig 1). Six hours after the x-ray she developed severe central abdominal pain followed by the signs of generalised peritonitis. A plain X-ray abdomen in the erect posture showed free gas under the diaphragm.

An exploratory laparotomy was done. A perforation was found at the antimesenteric border of ileum about 2 feet proximal to the ileo-caecal junction. A 4 cm x 2.5 cm sized stone was found lying in the peritoneal cavity (Fig 2). The stone was removed and the perforation closed. There was dense adhesion at the gall bladder and duodenal region around a mass which was left undisturbed. The abdomen was closed with peritoneal drainage.

Accepted for Publication : August 1, 1986.
Address all communications to : Dr. S. M. Abbas Husain,
Resident Medical Officer, Surgical Unit I, Abbasi Shaheed
Hospital, Karachi.